Check for updates

Classification of Carotid Plaque Echogenicity by Combining Texture Features and Morphologic Characteristics

Xiaowei Huang, MS, Yanling Zhang, MD, Ming Qian, PhD, Long Meng, PhD, Yang Xiao, PhD, Lili Niu, PhD, Rongqin Zheng, MD, Hairong Zheng, PhD

Objectives—Anechoic carotid plaques on sonography have been used to predict future cardiovascular or cerebrovascular events. The purpose of this study was to investigate whether carotid plaque echogenicity could be assessed objectively by combining texture features extracted by MaZda software (Institute of Electronics, Technical University of Lodz, Lodz, Poland) and morphologic characteristics, which may provide a promising method for early prediction of acute cardiovascular disease.

Methods—A total of 268 plaque images were collected from 136 volunteers and classified into 85 hyperechoic, 83 intermediate, and 100 anechoic plaques. About 300 texture features were extracted from histogram, absolute gradient, run-length matrix, gray-level co-occurrence matrix, autoregressive model, and wavelet transform algorithms by MaZda. The morphologic characteristics, including degree of stenosis, maximum plaque intima-media thickness, and maximum plaque length, were measured by B-mode sonography. Statistically significant features were selected by analysis of covariance. The most discriminative features were obtained from statistically significant features by linear discriminant analysis. The K-nearest neighbor classifier was used to classify plaque echogenicity based on statistically significant and most discriminative features.

Results—A total of 30 statistically significant features were selected among the plaques, and 2 most discriminative features were obtained from the statistically significant features. The classification accuracy rates for 3 types of plaques based on statistically significant and most discriminative features were 72.03% ($\kappa = 0.571$; $P < .001$) and 88.14% ($\kappa = 0.820$; $P < .001$), respectively. The receiver operating characteristic curve for identifying anechoic plaques showed an area under the curve of 0.918 when the most discriminative features were used to train the classifier.

Conclusions—It is feasible to classify carotid plaque echogenicity by combining texture features extracted from sonograms by MaZda and morphologic characteristics.

Key Words—carotid plaques; K-nearest neighbor classifier; sonography; texture; vascular ultrasound

Hyperechoic plaques are dominated by fibrous tissue (and sometimes calcification) and have been shown to promote plaque stability, whereas anechoic plaques have a higher lipid content and macrophages (and sometimes hemorrhage) and have proven to be potentially unstable.[1–3] Rupture of unstable plaques is the leading cause of morbidity and mortality worldwide, as it may lead to myocardial infarction or stroke.[4,5] Therefore, classification of plaque echogenicity may contribute to the identification of unstable plaques and prevent acute cardiovascular disease.

Received September 1, 2015, from the Paul C. Lauterbur Research Center for Biomedical Imaging, Institute of Biomedical and Health Engineering, Shenzhen Institutes of Advanced Technology, Chinese Academy of Sciences, Shenzhen, China (X.H., M.Q., L.M., Y.X., L.N., H.Z.); and Department of Ultrasound, Third Affiliated Hospital, Sun Yat-sen University, Guangzhou, China (Y.Z., R.Z.). Revision requested November 3, 2015. Revised manuscript accepted for publication January 5, 2016.

This work was supported by the National Science Foundation (grants 81527901, 11325420, 11302239, 11574341, 11304341, and 11272329). Xiaowei Huang, and Yanling Zhang contributed equally to this work.

Address correspondence to Lili Niu, PhD, Paul C. Lauterbur Research Center for Biomedical Imaging, Chinese Academy of Sciences, 1068 Xueyuan Ave, Nanshan District, 518055 Shenzhen, China.

E-mail: replace with ll.niu@siat.ac.cn

Abbreviations
ROI, region of interest

doi:10.7863/ultra.15.09002

Assessment of carotid plaque echogenicity on B-mode sonograms has been an effective way to predict the risks of cerebrovascular and cardiovascular events.[6–8] The grayscale median is a common and useful method for evaluating the sonographic echogenicity of carotid plaques,[6,9–13] but it ignores information about plaque structure, components, and morphologic characteristics. Texture analysis, including structural, model based, statistical, and transform methods, can obtain more information from medical images.[14] Previous studies have explained that texture analysis could discriminate symptomatic carotid plaques from asymptomatic plaques successfully.[15–17] Therefore, texture analysis may be a useful tool for classifying carotid plaque echogenicity.

MaZda (Institute of Electronics, Technical University of Lodz, Lodz, Poland) is a software package for 2- and 3-dimensional image texture analysis. MaZda provides a complete path for quantitative analysis of image textures, including computation of texture features, procedures for feature selection and extraction, algorithms for data classification, and various data visualization and image segmentation tools.[18] The software has been used to analyze magnetic resonance images of the human liver,[19] sonograms of myocardial tissue,[20] and radiographs of bone in rat models.[21] Thus, in this study, MaZda was been used to extract the texture features of carotid plaques and to classify plaque echogenicity.

In addition, plaque morphologic characteristics obtained by B-mode sonography, such as the degree of stenosis,[17] maximum plaque intima-media thickness,[12,15,22] and maximum plaque length,[15,16] have been considered risk factors for cardiovascular and cerebrovascular disease. Therefore, this study investigated whether carotid plaque echogenicity could be assessed by combining texture features and morphologic characteristics and could provide a promising method of early diagnosis of acute cardiovascular disease.

Materials and Methods

Image Acquisition and Preprocessing

Our study population consisted of 136 volunteers from the Third Affiliated Hospital of Sun Yat-sen University (Guangzhou, China), who were enrolled from October 2011 to February 2015. The study protocol was approved by the Institutional Review Board of the Third Affiliated Hospital of Sun Yat-sen University, and written informed consent was obtained from the participants. The study was performed by a sonographer with 5 years of experience in vascular imaging using an Aplio XG SSA-790A ultrasound platform (Toshiba Medical Systems Co, Ltd, Tokyo, Japan) equipped with a 5–12-MHz linear array transducer (PLT-805AT) and a MyLab 90 ultrasound platform (Esaote Medical Systems, Genoa, Italy) equipped with a 4–13-MHz linear-array transducer (LA523).

A total of 275 carotid plaque sonograms were obtained. Plaque echogenicity was characterized according to the criteria of the European Carotid Plaque Study Group: echogenicity was evaluated using a scale of 1 to 3, where 1 denoted anechoic, 2 intermediate, and 3 hyperechoic.[23] All images were classified by 2 experienced vascular sonographers independently. The between-observer reproducibility was evaluated by a κ value. In cases of disagreement, the controversial plaques were eliminated. The remaining 268 carotid plaque sonograms (85 hyperechoic, 83 intermediate, and 100 anechoic) were analyzed in this study. The plaques were randomly divided into a training group (50 hyperechoic, 50 intermediate, and 50 anechoic) and a testing group (35 hyperechoic, 33 intermediate, and 50 anechoic).

The brightness and contrast of a B-mode image strongly depend on the system gain, time-gain compensation, and dynamic range. Images obtained by different sonographers and different ultrasound systems at different settings may be different. Thus, images were normalized before texture analysis. The normalization adjusted the images linearly in Photoshop software (Adobe Systems, San Jose, CA) according to the method proposed by Sabetai et al,[24] so that the grayscale median of the blood was 0 to 5, and the grayscale median of adventitia was 185 to 195. Figure 1 illustrates a flowchart of carotid plaque echogenicity classification.

Region of Interest Selection

In MaZda, regions of interest (ROIs) can be drawn with different colors and arbitrary shapes.[18] Regions of interest were selected by an experienced vascular sonographer. Figure 2 shows ROIs drawn on B-mode sonograms of carotid plaques.

Texture Feature Extraction

Texture refers to the appearance, structure, and arrangement of the parts of an object within an image.[14] In MaZda, about 300 texture features are extracted on the basis of the following algorithms: histogram, absolute gradient, run-length matrix, co-occurrence matrix, autoregressive model, and wavelet transform, as shown in Table 1.[18,25] A report is generated when texture analysis is implemented for an ROI. The report can be used as an interface for users.

15509613, 2016, 10, Downloaded from https://onlinelibrary.wiley.com/doi/10.7863/ultra.15.09902 by Cas - Shanghaitech University, Wiley Online Library on [21/09/2025]. See the Terms and Conditions (https://onlinelibrary.wiley.com/terms-and-conditions) on Wiley Online Library for rules of use; OA articles are governed by the applicable Creative Commons License

Morphologic Characteristics

Morphologic characteristics, including degree of stenosis, maximum intima-media thickness, and maximum length of the plaque, were measured with calipers on frozen images during the scanning by the sonographer. The morphologic characteristics and texture features extracted by MaZda were used to classify the carotid plaques.

Feature Selection Method and Classification

Statistically significant features were selected among the texture features and morphologic characteristics. To improve the accuracy of classification, linear discriminant analysis was implemented for statistically significant features using MaZda to obtain the most discriminative features. In addition, the ability of the grayscale median to classify plaques with different echogenicity was examined. Thus, the K-nearest neighbor classifier was used to classify 3 types of plaques based on the grayscale median, statistically significant features, and most discriminative features.

Interoperator Agreement

To examine the interoperator agreement, the other operator performed the scheme with the same training and testing group data. The operator drew ROIs independently and selected the same features as the first operator for classification. The interoperator agreement was calculated as a κ value.

Statistical Analyses

All statistical analyses were performed with PASW Statistics version 18 software (IBM Corporation, Armonk, NY), and $P < .05$ was considered statistically significant. All values are reported as mean ± standard deviation or number of participants and percentage. Analysis of covariance, adjusted with age as a covariate, was used to examine which features were significantly different between hyperechoic, intermediate, and anechoic plaques. Analysis of covariance was also performed for the most discriminative features. The between-observer agreement on visual classification,

Figure 1. Flowchart of carotid plaque classification based on texture features and morphologic characteristics. Processes in yellow boxes were performed in MaZda.

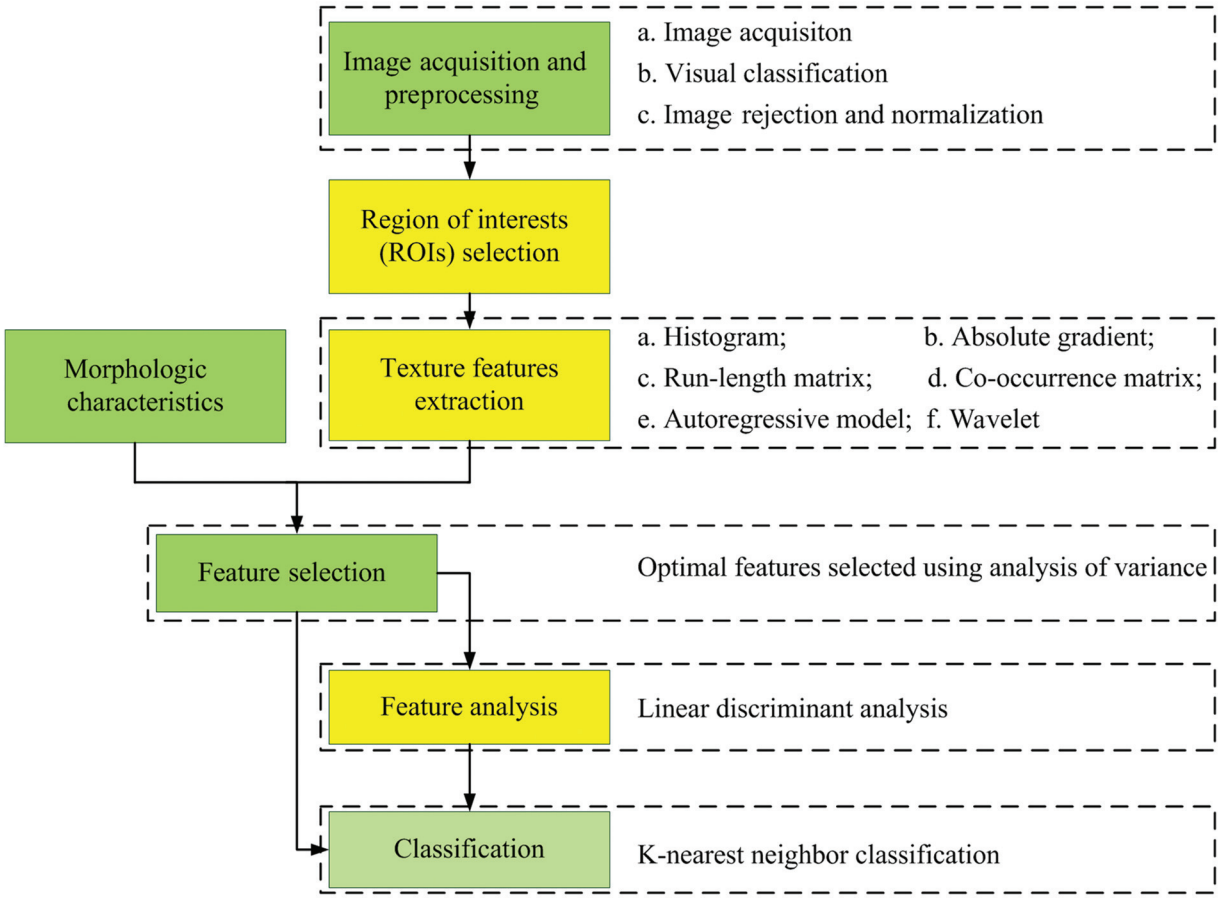

15509613, 2016, 10, Downloaded from https://onlinelibrary.wiley.com/doi/10.7863/ultra.15.09002 by Cas - Shanghaitech University, Wiley Online Library on [21/09/2025]. See the Terms and Conditions (https://onlinelibrary.wiley.com/terms-and-conditions) on Wiley Online Library for rules of use; OA articles are governed by the applicable Creative Commons License

consistency between visual classification, and K-nearest neighbor classification and interoperator agreement on classification based on most discriminative features were calculated as κ values.

Results

Clinical Characteristics of the Study Participants

A total of 268 plaques from 136 participants were analyzed in this study. The baseline characteristics are summarized in Table 2.

Visual Classification

The visual classification showed good agreement between the observers (n = 275), as shown in Table 3. The between-observer reproducibility was 97.45% (κ = 0.962), and the disagreements between the observers (n = 7) were excluded from the following analyses.

Feature Extraction and Classification

For texture features extracted by MaZda and morphologic characteristics measured by the sonographer, the means and standard deviations for hyperechoic, intermediate, and

Figure 2. Carotid plaques in an 81-year-old man. **A**–**C**, Original images from the Aplio XG SSA-790A system showing anechoic (**A**), intermediate (**B**), and hyperechoic (**C**) plaques. **D**–**F**, Normalized images corresponding to **A**–**C** for ROI definition.

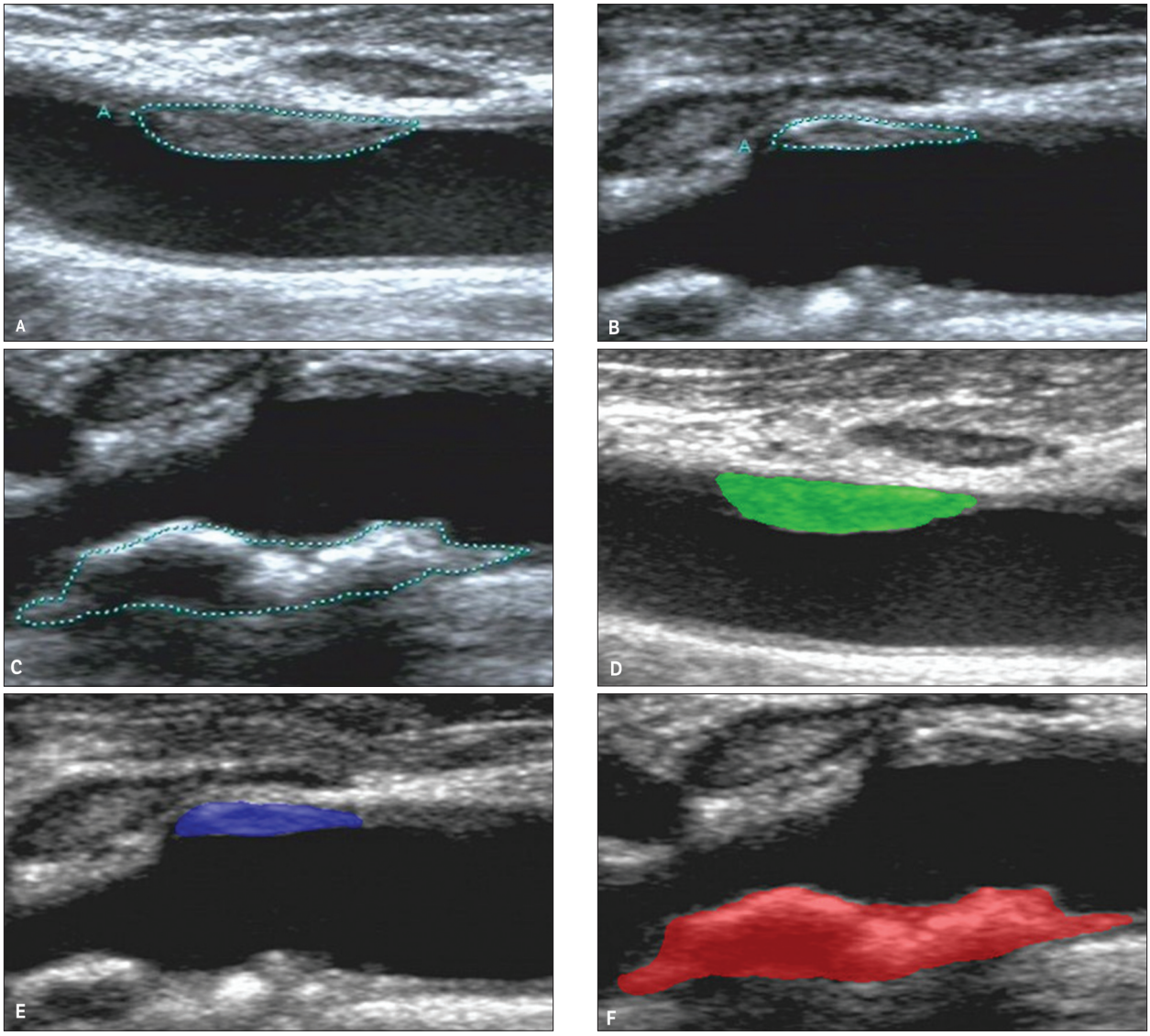

15509613, 2016, 10, Downloaded from https://onlinelibrary.wiley.com/doi/10.7863/ultra.15.09002 by Cas - Shanghaitech University, Wiley Online Library on [21/09/2025]. See the Terms and Conditions (https://onlinelibrary.wiley.com/terms-and-conditions) on Wiley Online Library for rules of use; OA articles are governed by the applicable Creative Commons License

Table 1. Texture Features Used in the Study

Algorithm	Texture Features
Histogram	Mean, variance, skewness, kurtosis, and 1st, 10th, 50th, 90th, and 99th percentiles
Absolute gradient	Mean, variance, skewness, kurtosis, and percentage of pixels with nonzero gradient
Run-length matrix	Run-length nonuniformity, gray-level nonuniformity, long-run emphasis, short-run emphasis, and fraction of image in runs; parameters computed for horizontal, 45°, vertical, and 135° directions
Co-occurrence matrix	Angular second moment, contrast, correlation, sum of squares, inverse difference moment, sum average, sum variance, sum entropy, entropy, difference variance, and difference entropy; parameters computed for 4 directions: (a, 0), (0, a), (a, a), (a, –a) and 5 distances: a = 1, 2, 3, 4, 5, between image pixels
Autoregressive model	Model parameter vector includes 4 parameters; SD of the driving noise
Wavelet	Energy of wavelet coefficients in low-frequency sub-bands, horizontal high-frequency sub-bands, vertical high-frequency sub-bands, and diagonal high-frequency sub-bands at successive scales

anechoic plaques were computed, and P values were obtained by analysis of covariance, adjusted with age as a covariate. A total of 30 features (28 texture features and 2 morphologic characteristics) were considered statistically significant features, as shown in Table 4.

For training the classifier, 50 hyperechoic, 50 intermediate, and 50 anechoic plaques were used, whereas for testing the classifier, the remaining 35 hyperechoic, 33 intermediate, and 50 anechoic plaques were used. The classification accuracy for plaques based on statistically significant features was 72.03% ($\kappa = 0.571$; $P < 0.001$), as shown in Table 5. Among the 33 misclassifications, 23 occurred between intermediate and anechoic plaques; 5 occurred between hyperechoic and intermediate plaques; and 5 occurred between hyperechoic and anechoic plaques. A linear discriminant analysis was run for statistically significant features using MaZda. Table 6 shows the 2 most discriminative features obtained from statistically significant features that achieved statistical significance. Figure 3 shows a scatterplot of the K-nearest neighbor classifier (K = 3) using most discriminative features 1 and 2 for 268 carotid plaques. The classification accuracy for plaques based on the most discriminative features was 88.14% ($\kappa = 0.820$; $P < .001$), as shown in Table 7. Among the 14 misclassifications, 9 occurred between intermediate and anechoic plaques, and 5 occurred between hyperechoic and intermediate plaques.

Identification of Anechoic Plaques

Anechoic plaques have proven to be potentially unstable and have been regarded as high-risk plaques, whereas hyperechoic and intermediate plaques have been considered low risk.[2,3] Therefore, identifying high-risk plaques is of great clinical importance. A receiver operating characteristic (ROC) analysis was implemented to identify anechoic plaques. Figure 4 shows the receiver operating characteristic curves for the K-nearest neighbor classifier when statistically significant and most discriminative features were used to train the classifier. When the classifier was trained with the most discriminative features, the area under the curve was significantly higher at 0.918, whereas the value when trained with the statistically significant features was 0.760.

Table 2. Baseline Characteristics of the 136 Participants

Characteristic	Value
Age, y	68.7 ± 9.6
Male, n (%)	92 (67.6)
Hypertension, n (%)	91 (66.9)
Smoking, n (%)	54 (39.7)
Diabetes, n (%)	64 (47.1)
Congenital heart disease, n (%)	44 (32.4)
Systolic blood pressure, mm Hg	137.91 ± 21.92
Diastolic blood pressure, mm Hg	77.04 ± 11.63
Body mass index, kg/m^2	2.25 ± 0.30
Total cholesterol, mmol/L	4.52 ± 1.18
Triglycerides, mmol/L	1.51 ± 1.15
High-density lipoprotein cholesterol, mmol/L	1.09 ± 0.30
Low-density lipoprotein cholesterol, mmol/L	2.89 ± 0.99
Apolipoprotein A1, g/L	1.29 ± 0.28
Apolipoprotein B100, g/L	1.09 ± 0.36
Fasting blood glucose, mmol/L	6.81 ± 3.05

Data are presented as mean ± SD where applicable.

Table 3. Visual Classification of 275 Carotid Plaques by 2 Observers

Second Observer	First Observer			
	Hyperechoic	Intermediate	Anechoic	Total
Hyperechoic	85	0	0	85
Intermediate	2	83	0	85
Anechoic	1	4	100	105
Total	88	87	100	275

15509613, 2016, 10, Downloaded from https://onlinelibrary.wiley.com/doi/10.7863/ultra.15.09902 by Cas - Shanghaitech University, Wiley Online Library on [21/09/2025]. See the Terms and Conditions (https://onlinelibrary.wiley.com/terms-and-conditions) on Wiley Online Library for rules of use; OA articles are governed by the applicable Creative Commons License

Interoperator Agreement

The interoperator agreement was 88.13% (κ = 0.822) when the most discriminative features were used for classification.

Discussion

This study has shown that it is feasible to classify anechoic, intermediate, and hyperechoic plaques based on texture features extracted by MaZda and morphologic characteristics. Classification accuracy reached 88.14% (κ = 0.820; $P < .001$), and interoperator agreement was 88.13% (κ = 0.822) when the most discriminative features were used to train the classifier. Furthermore, Figure 4 shows that our method has high potential for identification of anechoic plaques (area under the curve, 0.918).

Mayor et al[11] compared visual analysis and the grayscale median to evaluate carotid plaque echogenicity. The grayscale median analysis was in agreement with visual classification: plaques of types 1 through 5 had intermediate mean grayscale medians of 33, 58, 100, 127, and 163, respectively. The mean grayscale median and types were related in a linear fashion (Spearman $r = 1$; $P < .05$), and grayscale medians between different types of plaques were

Table 4. Statistically Significant Texture Features and Morphologic Characteristics Extracted From 268 Sonograms of Carotid Plaques

No.	Feature	Hyperechoic (n = 85)	Intermediate (n = 83)	Anechoic (n = 100)	*F*	*P*
Histogram						
1	Mean	146.96 ± 28.44	100.50 ± 21.41	88.79 ± 19.95	153.92	<.001
2	Variance	1679 ± 742	1371 ± 697	564 ± 411	80.13	<.001
3	1st percentile	67.65 ± 20.85	42.71 ± 15.06	45.16 ± 15.68	54.35	<.001
4	50th percentile	144.96 ± 32.23	93.77 ± 21.88	86.61 ± 19.81	143.07	<.001
5	90th percentile	201.35 ± 32.95	149.20 ± 32.96	118.54 ± 26.70	168.08	<.001
6	99th percentile	231.07 ± 27.05	210.84 ± 32.71	153.07 ± 36.76	143.80	<.001
Absolute gradient						
7	Kurtosis	0.967 ± 0.997	2.518 ± 1.476	1.682 ± 1.243	32.30	<.001
Run-length matrix						
8	Horiz-RLNon	847 ± 696	2192 ± 1387	2626 ± 1600	45.07	<.001
Co-occurrence matrix						
9	S(0, 1)SumAve	65.78 ± 0.69	64.47 ± 0.53	64.29 ± 0.47	182.37	<.001
10	S(0, 2)SumAve	66.51 ± 1.10	64.52 ± 0.82	64.15 ± 0.71	183.73	<.001
11	S(0, 3)SumAve	66.87 ± 1.31	64.52 ± 1.06	64.01 ± 0.91	171.89	<.001
12	S(1, 0)SumAve	65.16 ± 0.32	64.43 ± 0.33	64.43 ± 0.32	151.29	<.001
13	S(1, 1)SumAve	65.86 ± 0.73	64.48 ± 0.53	64.30 ± 0.48	185.65	<.001
14	S(1, –1)SumAve	65.89 ± 0.70	64.49 ± 0.55	64.31 ± 0.48	196.67	<.001
15	S(2, 0)SumAve	65.59 ± 0.53	64.50 ± 0.40	64.47 ± 0.37	186.29	<.001
16	S(2, –2)SumAve	66.68 ± 1.10	64.56 ± 0.85	64.20 ± 0.73	198.43	<.001
17	S(2, 2)SumAve	66.61 ± 1.14	65.54 ± 0.83	64.16 ± 0.71	188.12	<.001
18	S(3, 0)SumAve	65.98 ± 0.73	64.56 ± 0.48	64.50 ± 0.44	194.48	<.001
19	S(3, –3)SumAve	67.06 ± 1.29	64.58 ± 1.08	64.09 ± 0.95	183.41	<.001
20	S(3, 3)SumAve	66.94 ± 1.35	64.54 ± 1.08	64.02 ± 0.91	172.74	<.001
21	S(4, 0)SumAve	66.32 ± 0.92	64.62 ± 0.56	64.52 ± 0.51	193.74	<.001
22	S(4, 0)IDM	0.208 ± 0.073	0.238 ± 0.044	0.178 ± 0.035	29.37	<.001
23	S(4, –4)SumAve	67.05 ± 1.52	64.57 ± 1.28	64.01 ± 1.15	134.42	<.001
24	S(5, 0)SumAve	66.62 ± 1.08	64.67 ± 0.64	64.54 ± 0.57	191.28	<.001
25	S(5, –5)SumAve	66.68 ± 2.24	64.56 ± 1.45	63.97 ± 1.33	62.44	<.001
Wavelet						
26	WavEnLL-1	16,991 ± 458	17,455 ± 291	17,668 ± 347	78.42	<.001
27	WavEnLL-2	15,267 ± 1,205	17,029 ± 706	17,537 ± 849	143.21	<.001
28	WavEnLL-3	12,555 ± 1,877	16,522 ± 1,447	17,640 ± 1,796	214.46	<.001
Morphologic characteristics						
29	IMT, mm	2.045 ± 0.785	2.944 ± 0.657	2.624 ± 0.627	21.96	<.001
30	Length, mm	6.616 ± 3.957	14.356 ± 5.899	14.897 ± 6.404	60.57	<.001

Data are presented as mean ± SD; analysis of covariance with age of 69.6 years as covariate. Horiz-RLNon indicates horizontal run-length nonuniformity; IDM, inverse difference moment; IMT, intima-media thickness; SumAve, sum average; and WavEnLL-3, energy of wavelet coefficients in low-frequency sub-bands. S(x, y) indicates parameters of the co-occurrence matrix computed for different directions and distances between image pixels; parameters computed for 4 directions: (a, 0), (0, a), (a, a), (a, –a), and 5 distances: a = 1, 2, 3, 4, 5, between image pixels.

15509613, 2016, 10, Downloaded from https://onlinelibrary.wiley.com/doi/10.7863/ultra.15.09002 by Cas - Shanghaitech University, Wiley Online Library on [21/09/2025]. See the Terms and Conditions (https://onlinelibrary.wiley.com/terms-and-conditions) on Wiley Online Library for rules of use; OA articles are governed by the applicable Creative Commons License

Table 5. Comparison of Visual and K-Nearest Neighbor Classifications Based on Statistically Significant Features

Visual Classification	K-Nearest Neighbor Classification			
	Hyperechoic	Intermediate	Anechoic	Total
Hyperechoic	30	3	2	35
Intermediate	2	18	13	33
Anechoic	3	10	37	50
Total	35	31	52	118

statistically significant ($P < .02$). However, only the grayscale median value was used to evaluate plaque echogenicity. In our study, 30 statistically significant features (28 texture features and 2 morphologic characteristics) were extracted from the carotid plaque sonograms. When we examined the ability of the grayscale median for classifying hyperechoic, intermediate, and anechoic plaques, an accuracy rate of 53.39% was obtained, whereas the values were 72.03% for statistically significant features and 88.14% for most discriminative features. Our results indicated that a combination of texture features and morphologic characteristics showed an improvement in classifying 3 types of plaques. Previous studies used texture analysis of B-mode sonograms of carotid atheromatous plaques.[15–17,26,27] Golemati et al[26] analyzed 19 plaques and found that several first-order texture features of the plaques were significantly different from those of surrounding tissue. In a study of 10 carotid plaques in vitro, Rakebrandt et al[27] reported that 5 separate texture feature classes were correlated with fibrin, elastin, calcium, hemorrhage, and lipid. In addition, some studies investigated the ability of texture analysis for identifying symptomatic and asymptomatic plaques,[15–17] but there are relatively few studies that have focused on stratifying the risk of plaques according to echogenicity. A total of 268 carotid plaques were analyzed in this study to examine whether texture analysis could assess carotid plaque echogenicity using MaZda. Among the approximately 300 texture features, 28 statistically significant features were obtained. The 28 statistically significant features included 17 features extracted by the co-occurrence matrix, 6 extracted by the histogram, 3 extracted by wavelet transform, 1 extracted by the absolute gradient, and 1 extracted by the run-length matrix. Furthermore, the morphologic characteristics were closely associated with plaque echogenicity. Hirano et al[22] found that the maximum plaque intima-

Figure 3. Scatterplot showing training data (n = 150) and classified data (n = 118) for the K-nearest neighbor classifier using most discriminative features (MDFs) 1 and 2; 1 indicates anechoic; 2, intermediate; and 3, hyperechoic plaques.

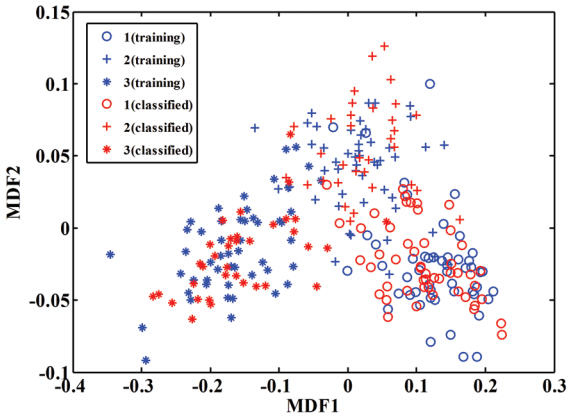

Figure 4. Receiver operating characteristic curves for identifying anechoic plaques for the K-nearest neighbor classifier using statistically significant features (SSFs) and most discriminative features (MDFs). AUC indicates area under the curve

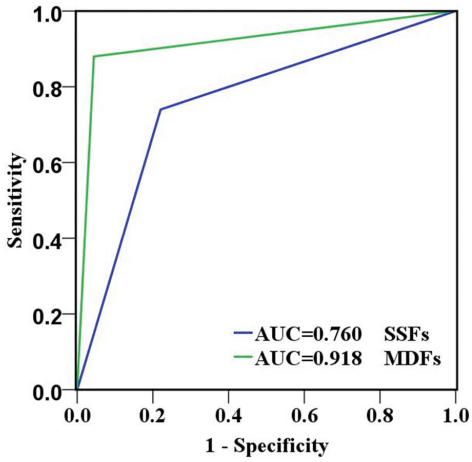

Table 6. Statistical Analysis of Most Discriminative Features

Feature	Hyperechoic (n = 85)	Intermediate (n = 83)	Anechoic (n = 100)	*F*	*P*
MDF1	−0.1594 ± 0.0684	0.0212 ± 0.0571	0.1179 ± 0.0571	483.43	<.001
MDF2	−0.0158 ± 0.0295	0.0465 ± 0.0320	−0.0251 ± 0.0317	136.42	<.001

Data are presented as mean ± SD; analysis of covariance. MDF indicates most discriminative feature.

15509613, 2016, 10, Downloaded from https://onlinelibrary.wiley.com/doi/10.7863/ultra.15.09002 by Cas - Shanghaitech University, Wiley Online Library on [21/09/2025]. See the Terms and Conditions (https://onlinelibrary.wiley.com/terms-and-conditions) on Wiley Online Library for rules of use; OA articles are governed by the applicable Creative Commons License

Table 7. Comparison of Visual and K-Nearest Neighbor Classifications Based on Most Discriminative Features

Visual Classification	K-Nearest Neighbor Classification			
	Hyperechoic	Intermediate	Anechoic	Total
Hyperechoic	32	3	0	35
Intermediate	2	28	3	33
Anechoic	0	6	44	50
Total	34	37	47	118

media thickness and echogenicity in combination had a significant incremental effect on the predictive value of conventional risk factors for coronary events. Hori et al[28] analyzed the relationship between plaque thickness and length using the Kruskal-Wallis test and found a correlation between them ($P < .001$). Our results showed that the maximum plaque intima-media thickness and length were significantly different among the hyperechoic, intermediate, and anechoic plaques, as shown in Table 4.

As shown in Table 3, 4 of 7 disagreements occurred between intermediate and anechoic plaques during the visual classification. Table 5 shows that 23 of 33 misclassifications occurred between anechoic and intermediate plaques. These results imply that it is difficult to discriminate anechoic plaques from intermediate plaques. To improve the accuracy of classification, the most discriminative features were obtained from statistically significant features. Table 7 shows that the number of misclassifications between anechoic plaques and intermediate plaques was reduced to 9 from 23, and no misclassifications occurred between hyperechoic and anechoic plaques. These results suggest that our study discriminated anechoic plaques from intermediate and hyperechoic plaques successfully.

Previous studies have demonstrated that plaques that appeared anechoic were associated with intraplaque hemorrhage,[3] a high risk of ischemic cerebrovascular events,1 and a high risk of carotid bifurcation lesions.[29] These findings may imply that our results offer valid proof for identifying cerebrovascular and cardiovascular events. Recent studies showed that an anechoic plaque appearance on sonography could be used to predict coronary events alone[9,30,31] or in combination with other parameters, such as embolic signals[32] and sonographic assessment of brachial endothelial vasomotor function.[7] Those findings may indicate that our results combined with those parameters could be strong predictors of future coronary events.

The main limitation of this study was that the morphologic characteristics were measured by only a single operator. However, the measurement, which was based on B-mode sonograms, has proven to be a very stable and mature method.[33] A second limitation was the comparatively small number of participants, especially younger volunteers. In this study, age was treated as a covariate to balance its possible influence on the statistical analysis. Further studies with larger populations need to be conducted to verify our results.

In conclusion, it is feasible to classify carotid plaque echogenicity based on texture features extracted by MaZda and morphologic characteristics. Thus, measurement of texture features, together with morphologic characteristics of plaques, may improve prediction of cardiovascular events.

References

1. Mathiesen EB, Bonaa KH, Joakimsen O. Echolucent plaques are associated with high risk of ischemic cerebrovascular events in carotid stenosis: The Tromso study. *Circulation* 2001; 103:2171–2175.
2. Nordestgaard BG, Gronholdt ML, Sillesen H. Echolucent rupture-prone plaques. *Curr Opin Lipidol* 2003; 14:505–512.
3. Grønholdt MLM, Wiebe BM, Laursen H, Nielsen TG, Schroeder TV, Sillesen H. Lipid-rich carotid artery plaques appear echolucent on ultrasound B-mode images and may be associated with intraplaque haemorrhage. *Eur J Vasc Endovasc Surg* 1997; 14:439–445.
4. Mozaffarian D, Benjamin EJ, Go AS, et al. Heart disease and stroke statistics—2015 update: a report from the American Heart Association. *Circulation* 2015; 131:e29–e322.
5. Lechareas S, Yanni AE, Golemati S, Chatziioannou A, Perrea D. Ultrasound and biochemical diagnostic tools for the characterization of vulnerable carotid atherosclerotic plaque. *Ultrasound Med Biol* 2016; 42:31–43.
6. Doonan RJ, Dawson AJ, Kyriacou E, et al. Association of ultrasonic texture and echodensity features between sides in patients with bilateral carotid atherosclerosis. *Eur J Vasc Endovasc Surg* 2013; 46:299–305.
7. Nakamura T, Kitta Y, Uematsu M, et al. Ultrasound assessment of brachial endothelial vasomotor function in addition to carotid plaque echolucency for predicting cardiovascular events in patients with coronary artery disease. *Int J Cardiol* 2013; 167:555–560.
8. Nakamura T, Tsutsumi Y, Shimizu Y, Uchiyama S. Ulcerated carotid plaques with ultrasonic echolucency are causatively associated with thromboembolic cerebrovascular events. *J Stroke Cerebrovasc Dis* 2013; 22:93–99.
9. Reiter M, Effenberger I, Sabeti S, et al. Increasing carotid plaque echolucency is predictive of cardiovascular events in high-risk patients. *Radiology* 2008; 248:1050–1055.
10. Grogan JK, Shaalan WE, Cheng H, et al. B-mode ultrasonographic characterization of carotid atherosclerotic plaques in symptomatic and asymptomatic patients. *J Vasc Surg* 2005; 42:435–441.
11. Mayor I, Momjian S, Lalive P, Sztajzel R. Carotid plaque: comparison between visual and grey-scale median analysis. *Ultrasound Med Biol* 2003; 29:961–966.

15509613, 2016, 10, Downloaded from https://onlinelibrary.wiley.com/doi/10.7863/ultra.15.09002 by Cas - Shanghaitech University, Wiley Online Library on [21/09/2025]. See the Terms and Conditions (https://onlinelibrary.wiley.com/terms-and-conditions) on Wiley Online Library for rules of use; OA articles are governed by the applicable Creative Commons License

12. Irie Y, Katakami N, Kaneto H, et al. The utility of ultrasonic tissue characterization of carotid plaque in the prediction of cardiovascular events in diabetic patients. *Atherosclerosis* 2013; 230:399–405.
13. Ruiz-Ares G, Fuentes B, Martínez-Sánchez P, Martínez-Martínez M, Díez-Tejedor E. Utility of the assessment of echogenicity in the identification of symptomatic carotid artery atheroma plaques in ischemic stroke patients. *Cerebrovasc Dis* 2011; 32:535–541.
14. Castellano G, Bonilha L, Li LM, Cendes F. Texture analysis of medical images. *Clin Radiol* 2004; 59:1061–1069.
15. Christodoulou CI, Pattichis CS, Pantziaris M, Nicolaides A. Texture-based classification of atherosclerotic carotid plaques. *IEEE Trans Med Imaging* 2003; 22:902–912.
16. Mougiakakou SG, Golemati S, Gousias I, Nicolaides AN, Nikita KS. Computer-aided diagnosis of carotid atherosclerosis based on ultrasound image statistics, Laws' texture and neural networks. *Ultrasound Med Biol* 2007; 33:26–36.
17. Kakkos SK, Nicolaides AN, Kyriacou E, et al. Computerized texture analysis of carotid plaque ultrasonic images can identify unstable plaques associated with ipsilateral neurological symptoms. *Angiology* 2011; 62: 317–328.
18. Szczypinski PM, Strzelecki M, Materka A, Klepaczko A. MaZda: a software package for image texture analysis. *Comput Methods Programs Biomed* 2009; 94:66–76.
19. Jirak D, Dezortova M, Taimr P, Hajek M. Texture analysis of human liver. *J Magn Reson Imaging* 2002; 15:68–74.
20. Punys V, Puniene J, Jurkevicius R, Punys J. Myocardium tissue analysis based on textures in ultrasound images. *Stud Health Technol Inform* 2005; 116:435–440.
21. Blouin S, Moreau MF, Basle MF, Chappard D. Relations between radiograph texture analysis and microcomputed tomography in two rat models of bone metastases. *Cells Tissues Organs* 2006; 182:182–192.
22. Hirano M, Nakamura T, Kitta Y, et al. Assessment of carotid plaque echolucency in addition to plaque size increases the predictive value of carotid ultrasound for coronary events in patients with coronary artery disease and mild carotid atherosclerosis. *Atherosclerosis* 2010; 211:451–455.
23. European Carotid Plaque Study Group. Reprinted article: "Carotid artery plaque composition—relationship to clinical presentation and ultrasound B-mode imaging." *Eur J Vasc Endovasc Surg* 2011; 42(suppl 1):S32–S38.
24. Sabetai MM, Tegos TJ, Nicolaides AN, Dhanjil S, Pare GJ, Stevens JM. Reproducibility of computer-quantified carotid plaque echogenicity: can we overcome the subjectivity? *Stroke* 2000; 31:2189–2196.
25. Materka A, Szczypinski P. MaZda user's manual. MaZda Manual website. http://www.eletel.p.lodz.pl/mazda/download/mazda_manual.pdf. Accessed June 10, 2014.
26. Golemati S, Tegos TJ, Sassano A, Nikita KS, Nicolaides AN. Echogenicity of B-mode sonographic images of the carotid artery: work in progress. *J Ultrasound Med* 2004; 23:659–669.
27. Rakebrandt F, Crawford DC, Havard D, Coleman D, Woodcock JP. Relationship between ultrasound texture classification images and histology of atherosclerotic plaque. *Ultrasound Med Biol* 2000; 26:1393–1402.
28. Hori E, Hayashi N, Hamada H, et al. A development of atheromatous plaque is restricted by characteristic arterial wall structure at the carotid bifurcation. *Surg Neurol* 2008; 69:586–591.
29. Biasi GM, Sampaolo A, Mingazzini P, De Amicis P, El-Barghouty N, Nicolaides AN. Computer analysis of ultrasonic plaque echolucency in identifying high risk carotid bifurcation lesions. *Eur J Vasc Endovasc Surg* 1999; 17:476–479.
30. Honda O, Sugiyama S, Kugiyama K, et al. Echolucent carotid plaques predict future coronary events in patients with coronary artery disease. *J Am Coll Cardiol* 2004; 43:1177–1184.
31. Gronholdt ML, Nordestgaard BG, Schroeder TV, Vorstrup S, Sillesen H. Ultrasonic echolucent carotid plaques predict future strokes. *Circulation* 2001; 104:68–73.
32. Topakian R, King A, Kwon SU, Schaafsma A, Shipley M, Markus HS. Ultrasonic plaque echolucency and emboli signals predict stroke in asymptomatic carotid stenosis. *Neurology* 2011; 77:751–758.
33. McCloskey K, Ponsonby AL, Carlin JB, et al. Reproducibility of aortic intima-media thickness in infants using edge-detection software and manual caliper measurements. *Cardiovasc Ultrasound* 2014; 12:18.

15509613, 2016, 10, Downloaded from https://onlinelibrary.wiley.com/doi/10.7863/ultra.15.09002 by Cas - Shanghaitech University, Wiley Online Library on [21/09/2025]. See the Terms and Conditions (https://onlinelibrary.wiley.com/terms-and-conditions) on Wiley Online Library for rules of use; OA articles are governed by the applicable Creative Commons License